

CORRECTION

Open Access



Correction: Oral mucosal changes caused by nicotine pouches: case series

Sintija Miluna-Meldere^{1*}, Sarlote Agate Vanka², Ingus Skadins², Juta Kroica², Maris Sperga³ and Dagnija Rostoka²

Correction: *Diagnostic Pathology* 19, 127 (2024)

<https://doi.org/10.1186/s13000-024-01549-3>

Following publication of the original article [1], the authors identified a duplicate figures.

The online version of the original article can be found at <https://doi.org/10.1186/s13000-024-01549-3>.

*Correspondence:

Sintija Miluna-Meldere
sintijamiluna@gmail.com

¹Department of Prosthetic Dentistry, Riga Stradins University, Riga, Latvia

²Department of Biology and Microbiology, Riga Stradins University, Riga, Latvia

³Department of Pathology, Riga Stradins University, Riga, Latvia



© The Author(s) 2025. **Open Access** This article is licensed under a Creative Commons Attribution-NonCommercial-NoDerivatives 4.0 International License, which permits any non-commercial use, sharing, distribution and reproduction in any medium or format, as long as you give appropriate credit to the original author(s) and the source, provide a link to the Creative Commons licence, and indicate if you modified the licensed material. You do not have permission under this licence to share adapted material derived from this article or parts of it. The images or other third party material in this article are included in the article's Creative Commons licence, unless indicated otherwise in a credit line to the material. If material is not included in the article's Creative Commons licence and your intended use is not permitted by statutory regulation or exceeds the permitted use, you will need to obtain permission directly from the copyright holder. To view a copy of this licence, visit <http://creativecommons.org/licenses/by-nc-nd/4.0/>.

The incorrect Fig. 9 is:

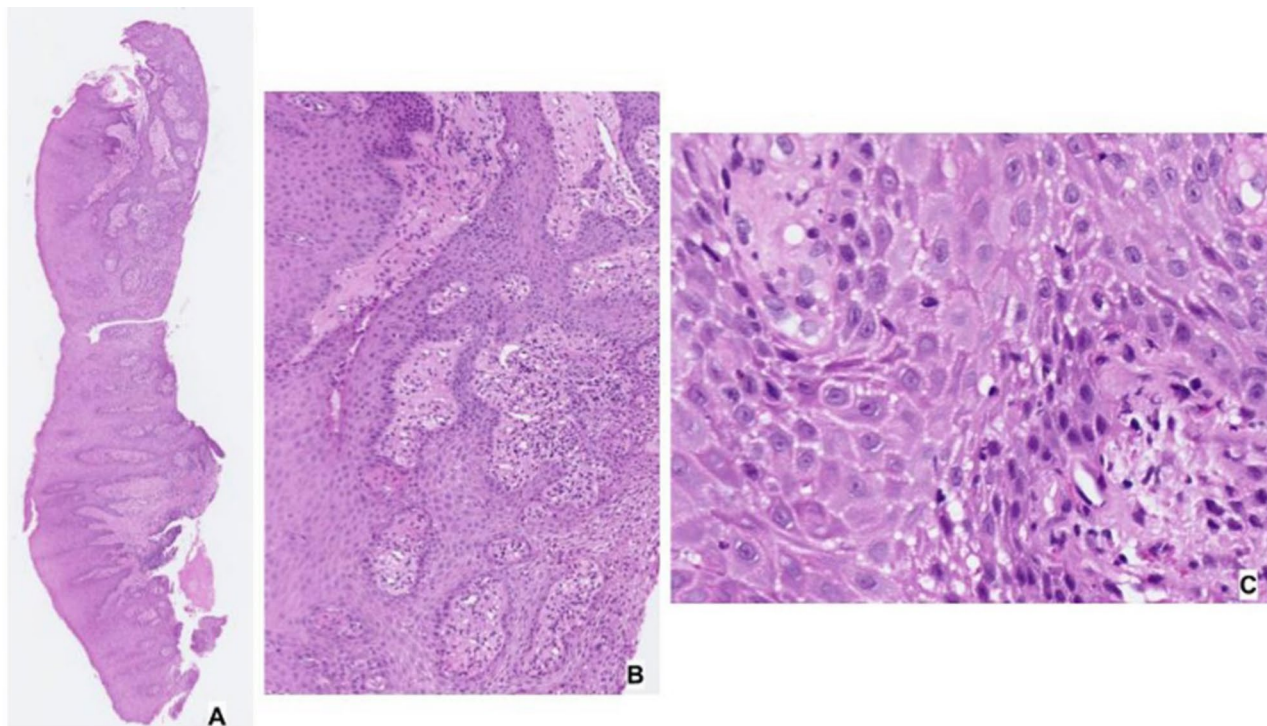


Fig. 9 Histopathological features of the oral lesions of Respondent No. 4. (H&E, original magnification 40x (A); 100x (B); 600x (C))

The correct Fig. 9 is:

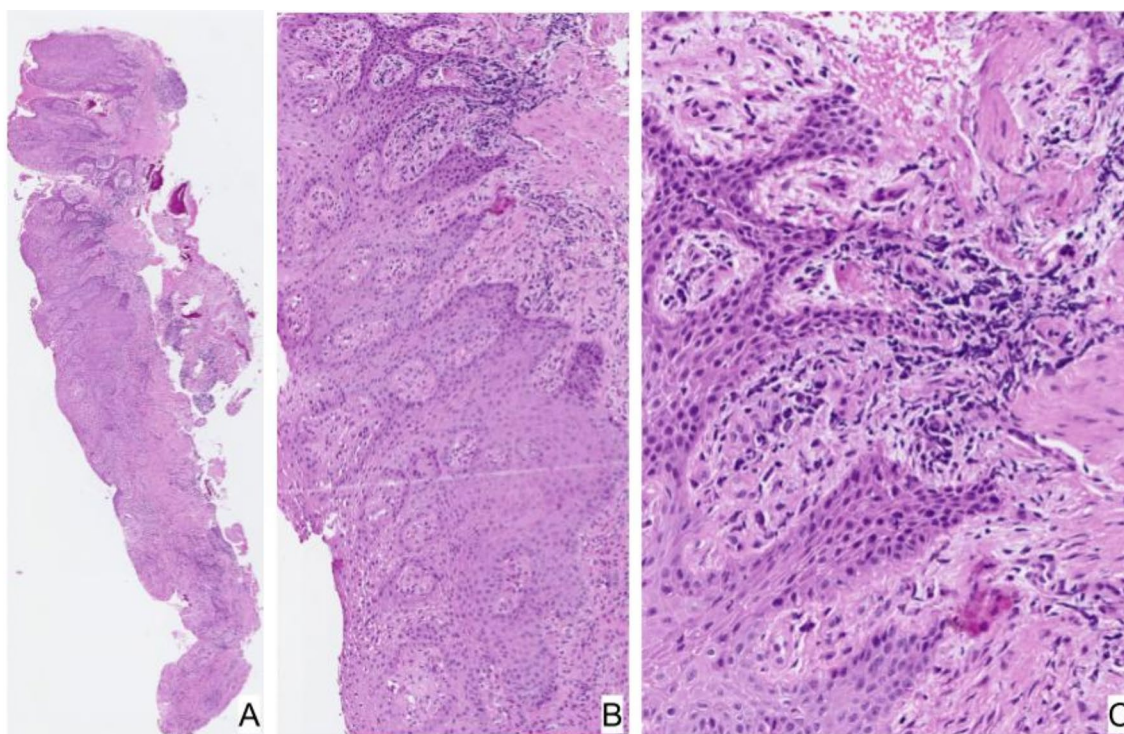


Fig. 9 Histopathological features of the oral lesions of Respondent No. 4. (H&E, original magnification 40x (A); 100x (B); 600x (C))

The original article [1] has been updated.

Published online: 28 January 2025

Publisher's note

Springer Nature remains neutral with regard to jurisdictional claims in published maps and institutional affiliations.

References

1. Miluna-Meldere S, Vanka SA, Skadins I, et al. Oral mucosal changes caused by nicotine pouches: case series. *Diagn Pathol.* 2024;19:127. <https://doi.org/10.1186/s13000-024-01549-3>.